

## **Conservative management of an extensive odontogenic keratocyst in the anterior region of a pediatric patient's jaw**

**Manejo conservador de extenso ceratocisto odontogênico em região anterior de mandíbula em paciente pediátrico**

**Tratamiento conservador de exuberante queratoquisto odontógeno en la región anterior mandibular del paciente pediátrico**

Received: 03/26/2021 | Reviewed: 03/31/2021 | Accept: 04/06/2021 | Published: 04/17/2021

### **Filipe Nobre Chaves**

ORCID: <https://orcid.org/0000-0001-6345-8156>  
Federal University of Ceará, Brazil  
E-mail: [filipenobrechaves@gmail.com](mailto:filipenobrechaves@gmail.com)

### **Jefferson Douglas Lima Fernandes**

ORCID: <https://orcid.org/0000-0002-5231-3813>  
Federal University of Ceará, Brazil  
E-mail: [jefferson.odonto97@gmail.com](mailto:jefferson.odonto97@gmail.com)

### **Samuel Rocha França**

ORCID: <https://orcid.org/0000-0001-6527-350X>  
Federal University of Ceará, Brazil  
E-mail: [samuelfranca@outlook.com](mailto:samuelfranca@outlook.com)

### **Denise Hélen Imaculada Pereira Oliveira**

ORCID: <https://orcid.org/0000-0001-6020-2374>  
Federal University of Ceará, Brazil  
E-mail: [denise.oliveira@sobral.ufc.br](mailto:denise.oliveira@sobral.ufc.br)

### **Marcelo Bonifácio da Silva Sampieri**

ORCID: <https://orcid.org/0000-0001-7942-6642>  
Federal University of Ceará, Brazil  
E-mail: [mar\\_sampieri@hotmail.com](mailto:mar_sampieri@hotmail.com)

### **Francisco Samuel Rodrigues Carvalho**

ORCID: <https://orcid.org/0000-0002-3142-1268>  
Federal University of Ceará, Brazil  
E-mail: [samuel.rcarvalho@gmail.com](mailto:samuel.rcarvalho@gmail.com)

### **Fábio Wildson Gurgel Costa**

ORCID: <https://orcid.org/0000-0002-3262-3347>  
Federal University of Ceará, Brazil  
E-mail: [fwildson@yahoo.com.br](mailto:fwildson@yahoo.com.br)

### **Karuza Maria Alves Pereira**

ORCID: <https://orcid.org/0000-0001-6345-8156>  
Federal University of Ceará, Brazil  
E-mail: [karuzaalves@yahoo.com.br](mailto:karuzaalves@yahoo.com.br)

### **Abstract**

Odontogenic keratocysts (OKCs) are now considered benign cysts of odontogenic origin that are characterized by an aggressive behavior with a relatively high recurrence rate, particularly when OKCs are associated with syndromes. Its histological appearance is characteristic with the presence of an epithelial lining parakeratinized showing a corrugated surface, together with a number of architectural features of the epithelium as a thickness of six to eight layers and the presence of columns, palisade basal cell. Radiographically, the lesion is often unilocular radiolucent surrounded by margins smooth or jagged edges with sclerotic. OKCs are more frequently in the third decade of life. This article reports a case of a young patient with exuberant OKC on unusual anterior mandibular site underwent treatment that involved a 48-month period of decompression, followed by enucleation of the residual cyst. Preserving important structures of the bone and soft tissue decompression is a method with low morbidity. In addition, according to the literature, decompression has a success rate at least as high as the one of most aggressive treatments.

**Keywords:** Odontogenic keratocysts; Marsupialization; Conservative treatment.

### **Resumo**

Ceratocistos odontogênicos (OKCs) são agora considerados cistos benignos odontogênicos caracterizados por comportamento agressivo com uma taxa de recorrência relativamente alta, particularmente quando OKCs estão

associados a síndromes. Seu aspecto histológico é característico, apresentando um revestimento epitelial paraqueratinizado exibindo superfície enrugada, soma-se juntamente com uma série de características arquitetônicas do epitélio, como uma espessura de seis a oito camadas e a presença de colunas em paliçado de células basais. Radiograficamente, a lesão é frequentemente radiotransparente unilocular cercada por margens lisas ou recortadas escleróticas. OKCs ocorrem mais frequentemente na terceira década de vida. Este artigo relata o caso de um paciente jovem com OKC exuberante em sítio mandibular anterior incomum, submetido a tratamento que envolveu um período de descompressão de 48 meses, seguido de enucleação do cisto residual. A preservação de estruturas importantes do osso e a descompressão de partes moles é um método de baixa morbidade. Além disso, de acordo com a literatura, a descompressão tem uma taxa de sucesso pelo menos tão alta quanto a dos tratamentos mais agressivos.

**Palavras-chave:** Ceratocistos odontogênicos; Marsupialização; Tratamento conservador.

### Resumen

Los queratoquistes odontogénicos (OKC) ahora se consideran quistes odontogénicos benignos caracterizados por un comportamiento agresivo con una tasa de recurrencia relativamente alta, particularmente cuando los OKC están asociados con síndromes. Su aspecto histológico es característico, presentando un revestimiento epitelial paraqueratinizado que muestra una superficie arrugada, que se suma a una serie de características arquitectónicas del epitelio, como un espesor de seis a ocho capas y la presencia de columnas en empalizada de células basales. Radiográficamente, la lesión suele ser unilocular radiolúcida rodeada de márgenes festoneados lisos o escleróticos. Los OKC ocurren con mayor frecuencia en la tercera década de la vida. En este artículo se reporta el caso de un paciente joven con CCC exuberante en un sitio mandibular anterior inusual, que fue sometido a un tratamiento que involucró un período de descompresión de 48 meses, seguido de enucleación del quiste residual. La preservación de estructuras óseas importantes y la descompresión de tejidos blandos es un método de baja morbilidad. Además, según la literatura, la descompresión tiene una tasa de éxito al menos tan alta como la de tratamientos más agresivos.

**Palabras clave:** Queratoquistes odontogénicos; Marsupialización; Tratamiento conservador.

## 1. Introduction

Odontogenic Keratocyst (OCK) is a benign lesion peculiar for its clinical behavior. First described by Philipsen in 1956 (Sharif F et al., 2010; Yildirim et al., 2010; Pogrel et al., 2015; Tabrizi et al., 2019), it was initially described as a cyst (Sharif F et al., 2010; Yildirim et al., 2010; Stoelinga et al., 2019), but the pathology has undergone classification changes, in 2005 it classified as a tumor (KCOT) due to studies revealing certain genetic molecular alterations also present in neoplasms (Sharif F et al., 2010; Pogrel et al., 2015; Antonoglou et al., 2014; Bhargava et al., 2012; Guo et al., 2013; Sansare et al., 2013; Sharif et al., 2015; Wright et al., 2014) . Yet in 2017, during the latest classification by the World Health Organization (WHO) - Head and Neck Tumors, it returned as an Odontogenic Keratocyst (OCK) (Stoelinga et al., 2019; Bilodeau et al., 2017; Speight et al., 2017).

Keratocystic odontogenic tumors affect a wide age range of patients, being most prevalent in the 2nd and 3rd decades of life, with certain studies show a slight predilection for males (1.7:1). Most lesions are asymptomatic and are found during routine imaging exams. They present standard infiltration characteristics and are associated with high recurrence rates. (Cunha et al., 2016; Al-Moraissi et al., 2016; Johnson et al., 2013).

The imaging appearance of an OCK can vary from a small unilocular radiolucent image to a larger multilocular radiolucency, presenting a differential diagnosis from other osteo-destructive lesions, such as: ameloblastoma, dentigerous cyst, lateral periodontal cyst, and root cyst (Speight et al., 2017; Nayak et al., 2013; Polak et al., 2019). OCK can occur in any region of the mandible, however there is a predilection for the posterior or lower portions of the mandibular branch (Sansare et al., 2013; Chrcanovic et al., 2016; de Souza et al., 2010; Slusarenko et al., 2019).

Several OCK treatments are described in the literature (Sharif F et al., 2010; Yildirim et al., 2010; Tabrizi et al., 2019; Sharif et al., 2015; Al-Moraissi et al., 2016; Slusarenko et al., 2019; Kshirsagar et al., 2019; de Castro et al., 2018; Al-Moraissi et al., 2017; Blanas et al., 2000; Dammer et al., 1997; Marker et al., 1996), and range from conservative techniques to more invasive surgeries. Conservative approaches allow for tissue maintenance and less aesthetic-functional damage. Marsupialization (Tabrizi et al., 2019; Slusarenko et al., 2019) and enucleation (Slusarenko et al., 2019) are common, yet these

treatment modes present high recurrence rates (Cunha et al., 2016; Al-Moraissi et al., 2016; Johnson et al., 2013; Slusarenko et al., 2019; Al-Moraissi et al., 2017). Radical surgical treatment presents lower recurrence rates, however produces greater aesthetic-functional impairment and affects patient quality of life (Al-Moraissi et al., 2016; Al-Moraissi et al., 2017). To reduce recurrence rates, combinations of a conservative treatment with adjuvant therapies remains an alternative, and include using marsupialization or decompression techniques, associated with enucleation and peripheral osteotomy, or cryotherapy, or Carnoy's solution, (Al-Moraissi et al., 2016; Al-Moraissi et al., 2017).

The aim of the present study is to report an atypical case of OCK in the anterior region of the mandible, in a female patient in her twenties, demonstrating conservative surgical management associated with adjuvant therapy, which achieved low morbidity with no evidence of recurrence.

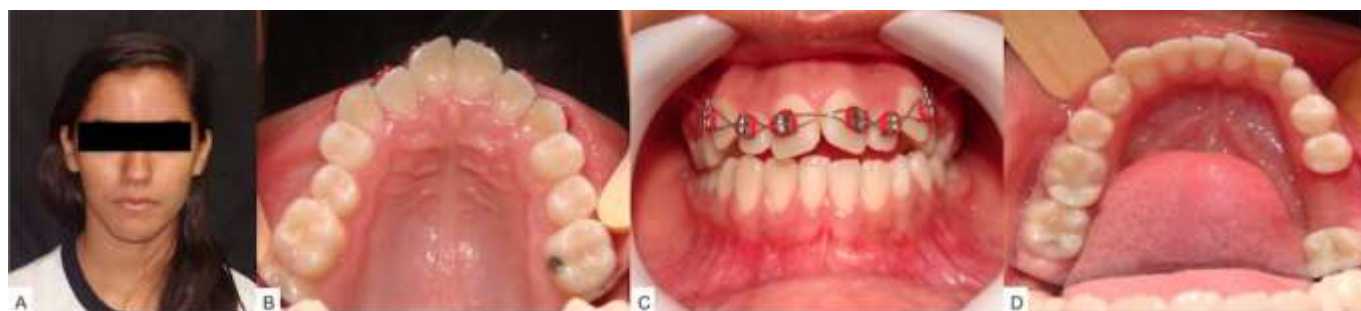## 2. Methodology

This article is a clinical case report with both a qualitative and descriptive approach. According to Estrela et al. (2018), such a study is characterized as a research in which direct data collection occurs, with the researcher being the primary instrument. This study was legally supported by an Informed Consent Form (TCLE) from the Federal University of Ceará - Campus Sobral. Stomatology Sector.

## 3. Case Report

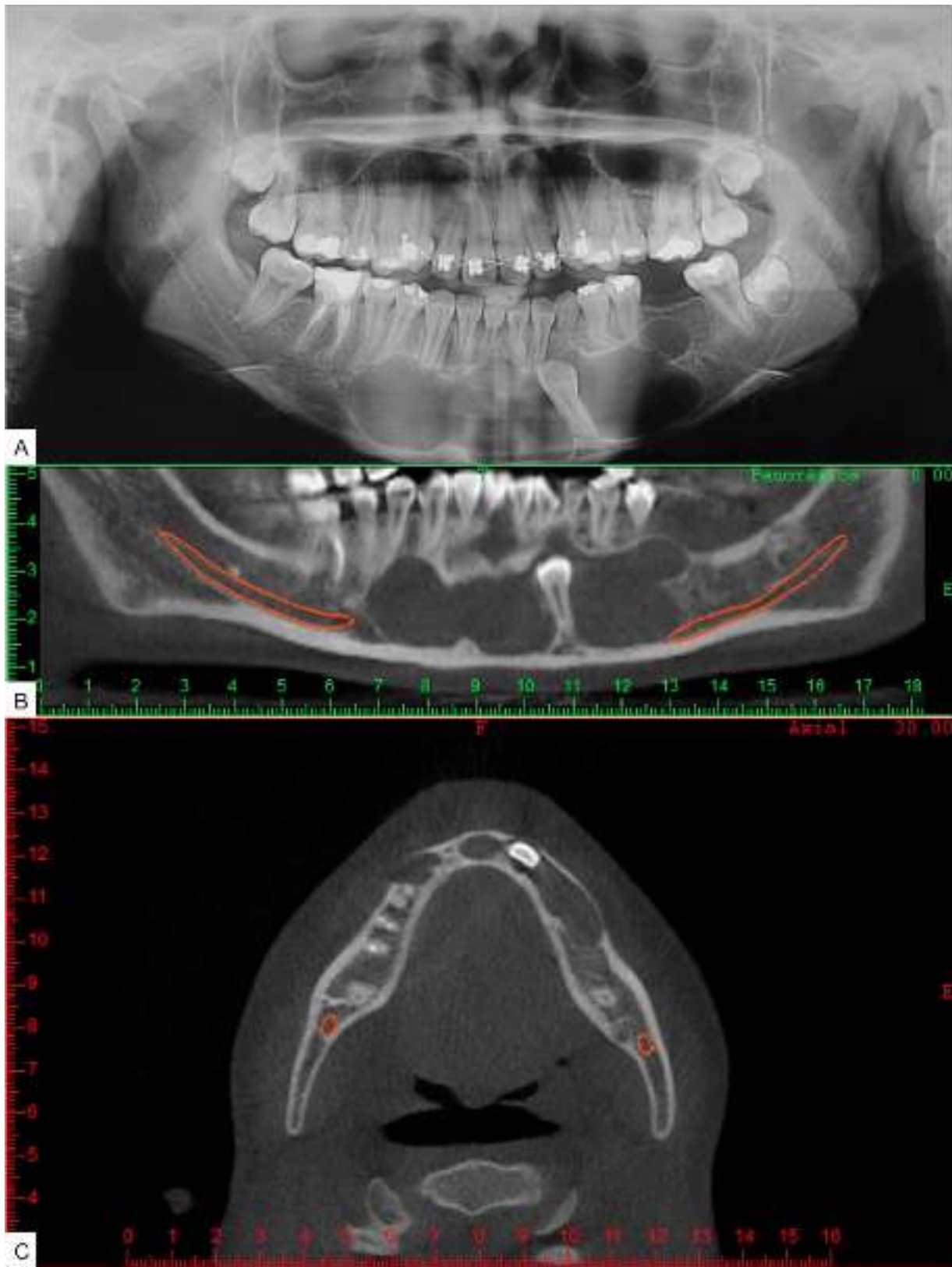
A female patient, 12 years old, sought care at the Stomatology Outpatient Clinic of the Federal University of Ceará, due to an intraosseous lesion discovered in a routine panoramic radiographic examination requested for orthodontic purposes. Extra-oral examination and oroscopy revealed no noteworthy alterations (Figure 1). Panoramic radiography revealed an extensive well-defined, unilocular, radiolucent, with irregular margins in the mandibular symphysis region extending to the posterior bilateral mandibular in the region of teeth 34 and 43, with approximate dimensions of greater than 4.0 cm x 1.5 cm (Figure 2), and (according to the patient) with an evolution time of approximately nine months.

**Figure 1.** Extra-oral examination (A) and oroscopy without significant alterations. Mention for absence of swelling or tooth displacement (B,C,D).



Source: Authors.

**Figure 2.** Panoramic radiography and computed tomography revealed an extensive radiolucent lesion in the mandibular symphysis region extending to the posterior bilateral mandibular in the region of teeth 34 and 43 (A). CT shows well-defined unilocular lesion without displacement of vestibular bone cortex (B, C).



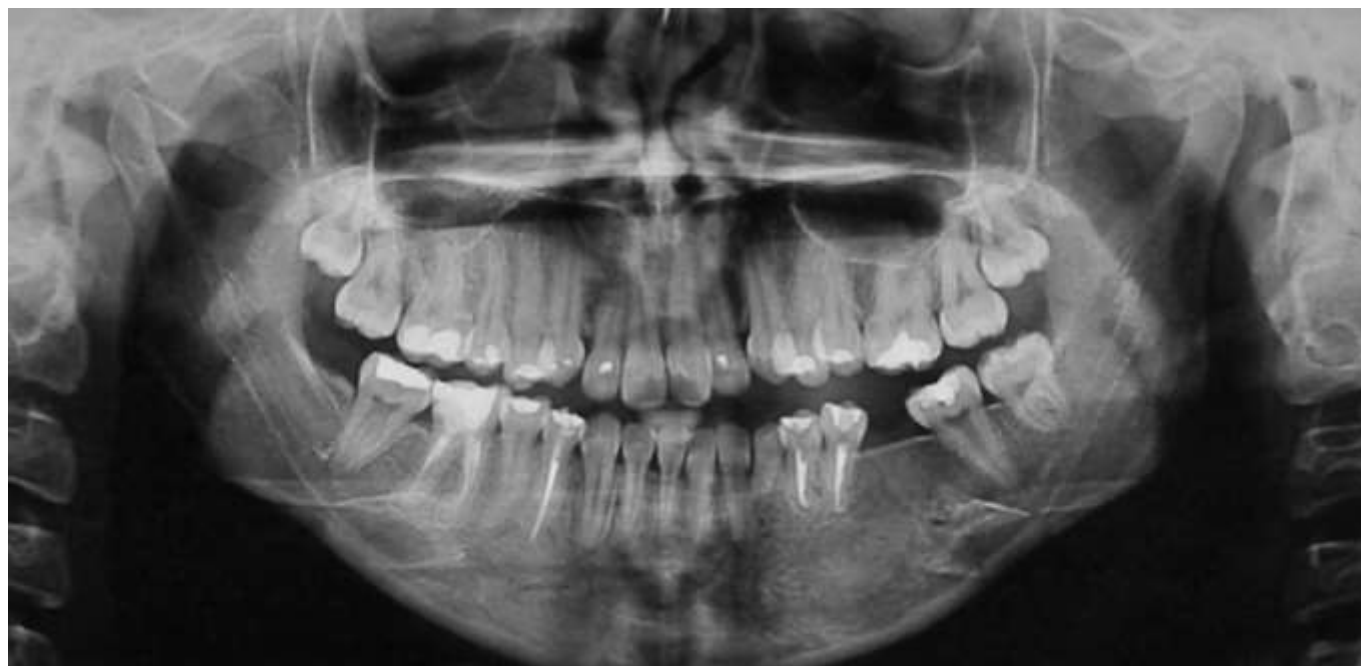Source: Authors.

After evaluating clinical and radiographic aspects, the diagnostic hypotheses were OCK, uni-cystic ameloblastoma, and dentigerous cyst. As an outpatient, and under local anesthesia, the patient underwent incisional biopsy as a special case after an aspiration puncture revealed a collection of yellow-citrus liquid.

The anatomopathological examination revealed fragments of a cystic lesion, characterized by a pathological cavity partially covered by para-keratinized stratified squamous epithelium, with a corrugated surface, a hyperchromatic and palisade basal layer, and a flat epithelial / conjunctive interface. The diagnostic hypothesis of OCK was confirmed.

After diagnosis, we chose to marsupialization the cystic lesion and follow with enucleation, and the lesion, associated with the included-tooth 33, was also removed. After 24 months of clinical and radiographic follow-up every six months, a recurrence was observed in the lower incisors region and a new surgical intervention was performed, enucleation was followed by peripheral osteotomy. Currently, the patient has for 4 years been undergoing radiographic follow-up since the last surgical procedure, with no signs of recurrence and with preservation of masticatory function and good aesthetics (Figure 3).

**Figure 3.** Radiographic findings after 4 years of radiographic follow-up, with no signs of recurrence.



Source: Authors.

#### 4. Discussion

As classified by WHO (2017) (Stoelinga et al., 2019; Bilodeau et al., 2017; Speight et al., 2017), OCK may represent a true cyst, but it is clear that it is not a common cystic lesion, this is perhaps due to factors inherent to the epithelium and the cystic capsule itself. The lesion is distinct and requires special consideration due to its aggressive clinical behavior and its high rate of recurrence, these factors are associated with the histopathological profile and characteristics inherent to the epithelium and the friable cystic capsule (Yildirim et al., 2010; Wright et al., 2014; Naruse et al., 2017).

OCK represents about 6 to 25.7% of odontogenic cysts (Nayak et al., 2013; Al-Moraissi et al., 2017), with a very wide age distribution that can vary from 8 to 82 years of age, yet with a prevalence for the 3rd and 4th decades of life (Speight et al., 2017; Slusarenko et al., 2019; da Silva et al., 2016). Retrospective and geographic distribution studies (de Souza et al., 2010; da Silva et al., 2016; Khosravi et al., 2013) reveal that that 64% of all OCKs occur in men, revealing its predilection for males (Cunha et al., 2016; Al-Moraissi et al., 2016; Johnson et al., 2013; de Souza et al., 2010; da Silva et al., 2016; Khosravi et

al., 2013). According to Bilodeau and Collins (2017) OCK also has a strong predilection for the mandible (50-75% of cases). The angle and mandibular branch are the most commonly affected sites (Sansare et al., 2013; Chrcanovic et al., 2016; de Souza et al., 2010; Slusarenko et al., 2019; Al-Moraissi et al., 2017). OCK is uncommon in the 2nd decade of life, and few reports include women in this age group, this is also true for the anterior mandibular region, which makes the present case atypical, and underlines its importance in terms of diagnosis.

Choice of treatment involves criteria such as location and extent of the lesion. For lesions of up to 1cm in diameter, conservative treatment is recommended. However, lesions greater than 1cm require aggressive treatment. This is due to the potential for local invasion of the lesion (Polak et al., 2019; Krosravi et al., 2013). However, the therapy chosen may directly influence the recurrence rate (Al-Moraissi et al., 2016; Kshirsagar et al., 2019; Al-Moraissi et al., 2017; Blanas et al., 2000; Dammer et al., 1997). Conservative treatment can increase the recurrences by up to 32.3%, whereas with radical treatment the rate can fall to 8% (Al-Moraissi et al., 2017). Currently there is no consensus in the literature establishing well-defined relationships between lesion size, the type of treatment instituted, and expected recurrence rates (Kshirsagar et al., 2019; Al-Moraissi et al., 2017), this is because studies remain reporting conservative treatments with significant success rates against recurrence (Yildirim et al., 2010).

Retrospective studies (de Souza et al., 2010; Khosravi et al., 2013) and systematic reviews with meta-analyses (Antonoglou et al., 2014) reveal that decompression, followed by enucleation or marsupialization presents recurrences ranging between 17–56% (Antonoglou et al., 2014; de Souza et al., 2010; Khosravi et al., 2013). However, if compared to more aggressive treatments, conservative approaches present certain advantages such as preservation of anatomical and dental structures, and being applicable to all age groups. (Yildirim et al., 2010; Kshirsagar et al., 2019; Dammer et al., 1997). More aggressive treatments, such as partial or total resection, do have a lower rate of recurrence at around 8% of cases (Kshirsagar et al., 2019; Al-Moraissi et al., 2017; Dammer et al., 1997), yet the patient's age, systemic condition, and aesthetic and functional factors must be pre-evaluated (Yildirim et al., 2010; Kshirsagar et al., 2019; Dammer et al., 1997).

How one approaches OCK is decisive for both the prognosis and the associated recurrence rates. Radical treatments such as resections have lower rates of recurrence, but bring significant aesthetic-functional impairment, impacting the patients' quality of life. Conservative treatments have higher recurrence rates, yet this also impacts patient quality of life, since they will likely have to undergo another surgical procedure, with the additional risk of a malignant transformation. One compromise might be association of a conservative treatment with adjuvant therapy such as Carnoy's solution or cryotherapy. This can reduce surgery sequels as well as lesion recurrences (Sharif et al.; 2010; Al-Moraissi et al., 2016; Johnson et al., 2013; de Castro et al., 2018; Al-Moraissi et al., 2017; Blanas et al., 2000; Dammer et al., 1997; Marker et al., 1996; Buchbender et al., 2018). To determine the best way of handling the patient with OCK, the professional must demonstrate good judgment when evaluating the lesion, its growth rate, and the degree of tissue invasion, this, in addition to factors such as patient collaboration and the need for long-term follow-up.

## 5. Conclusion

In the systematic review study with a meta-analysis, Al-Moraissi et al (2017) observed several therapeutic modalities for OCK and that are associated with different recurrence percentages, it is noteworthy to note that the associations of modalities result in a low lesion recurrence. Our therapeutic choice has a satisfactory recurrence rate (14.6%) and maintains the patient's functional and aesthetic anatomical contour. This was an unusual case of OCK affecting the anterior mandible region, and occurring in a female patient in adolescence. It was successfully treated with a conservative approach. In the present case, considering factors such as preservation of noble structures, and fewer patient comorbidities, and given the associated aesthetic

area (anterior mandibular region), and easy (outpatient) access to treatment, conservative treatment option was chosen. We observed that even when opting for a conservative treatment modality, giving priority to aesthetics, preservation of noble structures, and to lessened comorbidity, it has proved to be effective, yielding a good prognosis during the now five-years of patient follow-up.

## Acknowledgments

The authors would like to thank Profa. Dra. Ana Paula Negreiros Nunes Alves and Prof. Dr. Mário Rogério Lima Mota from the Laboratory of Oral Pathology of the Federal University of Ceará, Brazil, for the contribution in physical structure of his Laboratory.

## References

- Al-Moraissi, E. A., Dahan, A. A., Alwadeai, M. S., et al. (2017). What surgical treatment has the lowest recurrence rate following the management of keratocystic odontogenic tumor?: A large systematic review and meta-analysis. *J Craniomaxillofac Surg*, 45:131-44.
- Al-Moraissi, E. A., Pogrel, M. A., & Ellis, E. (2016). Does the Excision of Overlying Oral Mucosa Reduce the Recurrence Rate in the Treatment of the Keratocystic Odontogenic Tumor? A Systematic Review and Meta-Analysis. *Journal of Oral and Maxillofacial Surgery*, 74:1974-82.
- Antonoglou, G. N., Sandor, G. K., Koidou, V. P., et al. (2014). Non-syndromic and syndromic keratocystic odontogenic tumors: systematic review and meta-analysis of recurrences. *J Craniomaxillofac Surg*, 42:e364-71.
- Bhargava, D., Deshpande, A., & Pogrel, M. A. (2012). Keratocystic odontogenic tumour (KCOT)--a cyst to a tumour. *Oral Maxillofac Surg*, 16:163-70.
- Bilodeau, E. A., & Collins, B. M. (2017). Odontogenic Cysts and Neoplasms. *Surgical Pathology Clinics*, 10:177-222.
- Blanas, N., Freund, B., Schwartz, M., et al. (2000). Systematic review of the treatment and prognosis of the odontogenic keratocyst. *Oral Surg Oral Med Oral Pathol Oral Radiol Endod*, 90:553-8.
- Buchbender, M., Neukam, F. W., Lutz, R., et al. (2018). Treatment of enucleated odontogenic jaw cysts: a systematic review. *Oral Surg Oral Med Oral Pathol Oral Radiol*, 125:399-406.
- Chrcanovic, B. R., & Gomez, R. S. (2016). Peripheral calcifying cystic odontogenic tumour and peripheral dentinogenic ghost cell tumour: an updated systematic review of 117 cases reported in the literature. *Acta Odontologica Scandinavica*, 74:591-7.
- Cunha, J. F., Gomes, C. C., de Mesquita, R. A., et al. (2016). Clinicopathologic features associated with recurrence of the odontogenic keratocyst: a cohort retrospective analysis. *Oral Surgery, Oral Medicine, Oral Pathology and Oral Radiology*, 121:629-35.
- da Silva, L. P., Serpa, M. S., Tenório, J. R., et al. (2016) Retrospective study of 289 odontogenic tumors in a Brazilian population. . *Med Oral Patol Oral Cirurg Bucal*, 21:271-5.
- Dammer, R., Niederellmann, H., Dammer, P., et al. (1997). Conservative or radical treatment of keratocysts: a retrospective review. *Br J Oral Maxillofac Surg*, 35:46-8.
- de Castro, M. S., Caixeta, C. A., de Carli, M. L., et al. (2018). Conservative surgical treatments for nonsyndromic odontogenic keratocysts: a systematic review and meta-analysis. *Clin Oral Investig*, 22:2089-101.
- de Souza, L. B., Gordón-Núñez, M. A., Nonaka, C. F., et al. (2010). Odontogenic cysts: demographic profile in a Brazilian population over a 38-year period. *Med Oral Patol Oral Cir Bucal*, 15:e583-90.
- Estrela, C. (2018). Scientific Methodology: Science, Teaching, Research. *Editora Artes Médicas*.
- Guo, Y. Y., Zhang, J. Y., Li, X. F., et al. (2013). PTCH1 gene mutations in Keratocystic odontogenic tumors: a study of 43 Chinese patients and a systematic review. *PLoS One*, 8:e77305.
- Johnson, N. R., Batstone, M. D., & Savage, N. W. (2013). Management and recurrence of keratocystic odontogenic tumor: a systematic review. *Oral Surgery, Oral Medicine, Oral Pathology and Oral Radiology*, 116:e271-e6.
- Khosravi, N., Razavi, S. M., Kowkabi, M., et al. (2013). Demographic distribution of odontogenic cysts in Isfahan (Iran) over a 23-year period (1988-2010). *Dent Res J (Isfahan)*, 10:162-7.
- Kshirsagar, R. A., Bhende, R. C., Raut, P. H., et al. (2019). Odontogenic Keratocyst: Developing a Protocol for Surgical Intervention. *Ann Maxillofac Surg*, 9:152-7.
- Marker, P., Brondum, N., Clausen, P. P., et al. (1996). Treatment of a large odontogenic keratocyst by decompression and later cystectomy. *Oral Surg Oral Med Oral Pathol*, 82:122-31.

- Naruse, T., Yamashita, K., Yanamoto, S., et al. (2017). Histopathological and immunohistochemical study in keratocystic odontogenic tumors: Predictive factors of recurrence. *Oncol Lett*, 13:3487-93.
- Nayak, M. T., Singh, A., Singhvi, A., et al. (2013). Odontogenic keratocyst: What is in the name? *J Nat Sci Biol Med*, 4:282-5.
- Pogrel, M. A. (2015). The keratocystic odontogenic tumour (KCOT)--an odyssey. *Int J Oral Maxillofac Surg*, 44:1565-8.
- Polak, K., Jedrusik-Pawlowska, M., Drozdowska, B., et al. (2019). Odontogenic keratocyst of the mandible: A case report and literature review. *Dent Med Probl*, 56:433-6.
- Sansare, K., Raghav, M., Mupparapu, M., et al. (2013). Keratocystic odontogenic tumor: systematic review with analysis of 72 additional cases from Mumbai, India. *Oral Surg Oral Med Oral Pathol Oral Radiol*, 115:128-39.
- Sharif, F., Oliver, R., Sweet, C., et al. (2010). Interventions for the treatment of keratocystic odontogenic tumours (KCOT, odontogenic keratocysts (OKC)). *Cochrane Database Syst Rev*, CD008464.
- Sharif, F. N., Oliver, R., Sweet, C., et al. (2015). Interventions for the treatment of keratocystic odontogenic tumours. *Cochrane Database Syst Rev*, 2015:CD008464.
- Slusarenko da Silva, Y., Stoelinga, P. J. W., & Naclerio-Homem, M. D. G. (2019). Recurrence of nonsyndromic odontogenic keratocyst after marsupialization and delayed enucleation vs. enucleation alone: a systematic review and meta-analysis. *Oral Maxillofac Surg*, 23:1-11.
- Speight, P. M., & Takata, T. (2017). New tumour entities in the 4th edition of the World Health Organization Classification of Head and Neck tumours: odontogenic and maxillofacial bone tumours. *Virchows Archiv*, 472:331-9.
- Stoelinga, P. J. W. (2019). Keratocystic odontogenic tumour (KCOT) has again been renamed odontogenic keratocyst (OKC). *International Journal of Oral and Maxillofacial Surgery*, 48:415-6.
- Tabrizi, R., Hosseini Kordkheili, M. R., Jafarian, M., et al. (2019). Decompression or Marsupialization; Which Conservative Treatment is Associated with Low Recurrence Rate in Keratocystic Odontogenic Tumors? A Systematic Review. *J Dent (Shiraz)*, 20:145-51.
- Wright, J. M., Odell, E. W., Speight, P. M., et al. (2014). Odontogenic tumors, WHO 2005: where do we go from here? *Head Neck Pathol*, 8:373-82.
- Yildirim, G., Ataoglu, H., Kalayci, A., et al. (2010). Conservative Treatment Protocol for Keratocystic Odontogenic Tumour: a Follow-up Study of 3 Cases. *J Oral Maxillofac Res*, 1:e7.